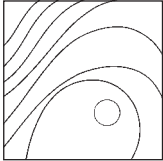


Platelet-Rich Fibrin as a Grafting Material in Periapical Surgery: A Case Series



Mihir R. Kulkarni, MDS¹
Jatinder Mohan, MDS²
Purva V. Bakshi, MDS³

Positive effects of platelet-rich fibrin (PRF) on soft tissue healing are well documented, but its role in hard-tissue healing remains contested. The present case series documents the use of PRF as the sole grafting material in periapical bone defects. PRF was prepared and condensed into the bone defects after debridement. The defects were then covered with a collagen membrane and wound closure was performed. In all three cases presented in this report, excellent bone fill was observed in the periapical defects. The observed benefit may be due to the role of fibrin in initial clot stabilization. The elaboration of various growth factors by the platelets and leukocytes in the PRF clot may also play a role. Int J Periodontics Restorative Dent 2019;39:e123–e127. doi: 10.11607/prd.3510

Bone loss due to periapical pathology is a common presentation encountered in clinical practice. There is ample evidence that this endodontically induced periradicular bone loss resolves spontaneously after a successful endodontic treatment, especially in cases of periapical abscess and pocket cysts.^{1–3} Adjuvant use of biocompatible materials like mineral trioxide aggregate (MTA)⁴ or calcium hydroxide⁵ can aid in this healing process. Some periapical lesions like true cysts may not heal spontaneously after endodontic therapy and may require a surgical intervention in the form of apicoectomy.¹ Surgical intervention may also be required in cases of endodontic mishaps such as perforation or instrument separation.

Numerous bone grafts and membranes have been used to surgically manage bone defects with varying success, but the benefit of using a bone graft and guided tissue regeneration (GTR) membranes in periapical surgery is unclear.⁶ Furthermore, the choice of a graft or membrane is influenced by many variables, such as availability, cost, and patient's consent, among others. There is also an added risk of graft infection, loss of graft, wound dehiscence, or membrane exposure during healing.⁷

Platelet-rich fibrin (PRF) has gained wide acceptance as a grafting material since its introduction by

¹Department of Periodontics, SDM College of Dental Sciences and Hospital, Sattur, Dharwad, Karnataka, India.

²School of Dental Medicine, University of Colorado, Denver, Colorado, USA.

³Vivekanand General Hospital, Deshpande Nagar, Hubballi, Karnataka, India.

Correspondence to: Dr Mihir R. Kulkarni, Department of Periodontics, SDM College of Dental Sciences and Hospital, Sattur, Dharwad – 580009, Karnataka, India.
Email: mihir.mrk271@gmail.com

Submitted July 13, 2017; accepted August 26, 2017.

©2019 by Quintessence Publishing Co Inc.

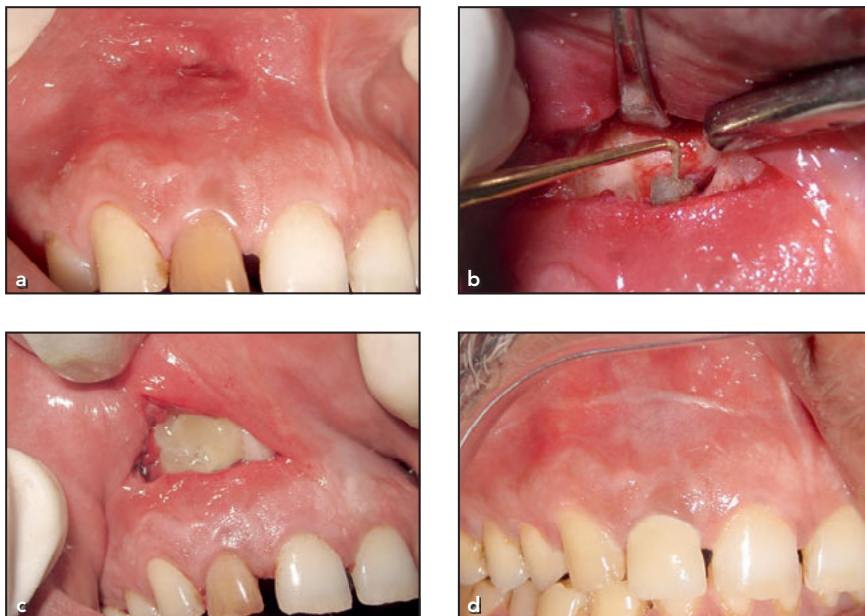

Fig 1 (a) Chronic periapical sinus. (b) Apicoectomy and retrograde restoration done. (c) Platelet-rich fibrin placed in the bone defect. (d) Wound healing seen at 6 months postoperative.

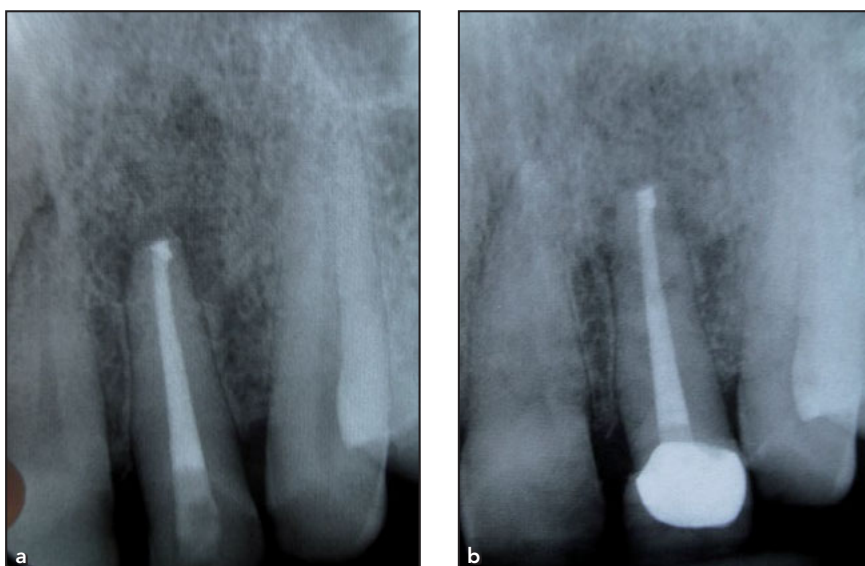


Fig 2 (a) Periapical radiograph taken immediately after the surgery. (b) Resolution of periapical lesion at 6 months postoperative.

Choukroun in 2001 due to its beneficial effects in wound healing.⁸ Ease of preparation and the relative lack of complications has made PRF a very safe and popular biomaterial leading to widespread use in regenerative procedures.⁹

The present case series aims to demonstrate the use of this PRF clot in three different clinical situations, namely apicoectomy, root resection, and cyst enucleation.

Case 1

A 54-year-old man presented with a nonhealing sinus in relation to the maxillary right lateral incisor. The patient was scheduled for periapical surgery when the sinus failed to heal even after 3 months of repeated orthograde endodontic interventions (Fig 1a). Surgical access was gained to the root apex, apicoectomy was performed, and a retrograde restoration was done using MTA (Fig 1b). The bony crypt surrounding the root was thoroughly debrided, irrigated with 0.9 g/L saline, and filled with PRF (Fig 1c). No other graft material was used. Wound closure was obtained using 4-0 Polyglactin 910 sutures. The patient was recalled at 2 weeks, 1 month, and 6 months. Figure 1d shows the soft tissue healing at 6 months. A follow-up periapical radiograph was taken at 6 months. In comparison to the baseline radiograph (Fig 2a), resolution of the periapical bone loss was observed (Fig 2b).

Case 2

A 32-year-old man presented with persistent pain of an endodontically treated maxillary right first molar. A periapical radiograph revealed an instrument separation in the mesio-buccal root of the tooth (Fig 3a). A root resection was planned, as the instrument was located in the apical third of the root and an orthograde access was deemed difficult. During surgical sectioning and extraction of the mesiobuccal root (Fig 4a), a perforation of the maxillary sinus

occurred. A collagen membrane was used to plug the perforation (Fig 4b), and the bony crypt was filled with PRF (Fig 4c). The patient was recalled at 15 days, 3 months (Fig 4d), and 6 months, and was asymptomatic at all these visits. A follow-up radiograph at 3 months showed bone fill in the bony crypt (Fig 3b).

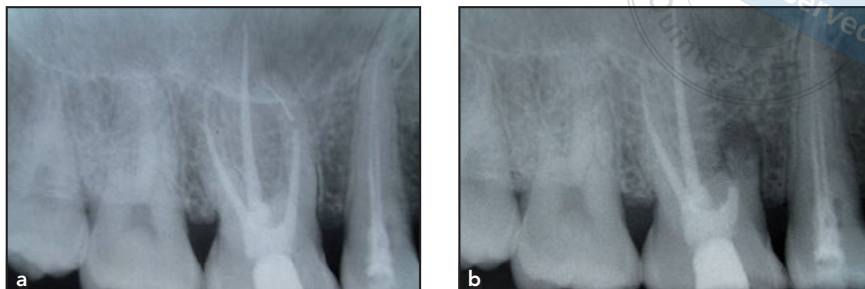

Fig 3 (a) Baseline radiograph showing instrument separation in the mesiobuccal root. (b) Radiograph at 3-month recall showing bone fill in the region of the resected root.

Case 3

A 24-year-old woman presented with pain and discoloration of the maxillary left central incisor. She reported trauma to the tooth 15 years ago. A radiograph revealed a periapical radiolucency involving the maxillary left central and lateral incisors (Fig 5a). Endodontic treatment of the teeth was completed. After 3 months, cone beam computed tomography was done and the patient underwent periapical surgery. On surgical entry, an intact cyst lining was encountered and the entire cyst was carefully dissected (Fig 6a); apicoectomy and retrograde restorations were performed on both the central and the lateral incisors (Fig 6b). The bony crypt was filled with PRF (Fig 6c) and covered with a collagen membrane (Fig 6d). The diagnosis of a radicular cyst was confirmed histopathologically. The patient was recalled after 15 days, 3 months, and 12 months. The patient was free of symptoms, soft tissue healing was satisfactory (Fig 7b), and the periapical region demonstrated radiographic evidence of bone formation at the 1-year recall visit (Fig 5b).

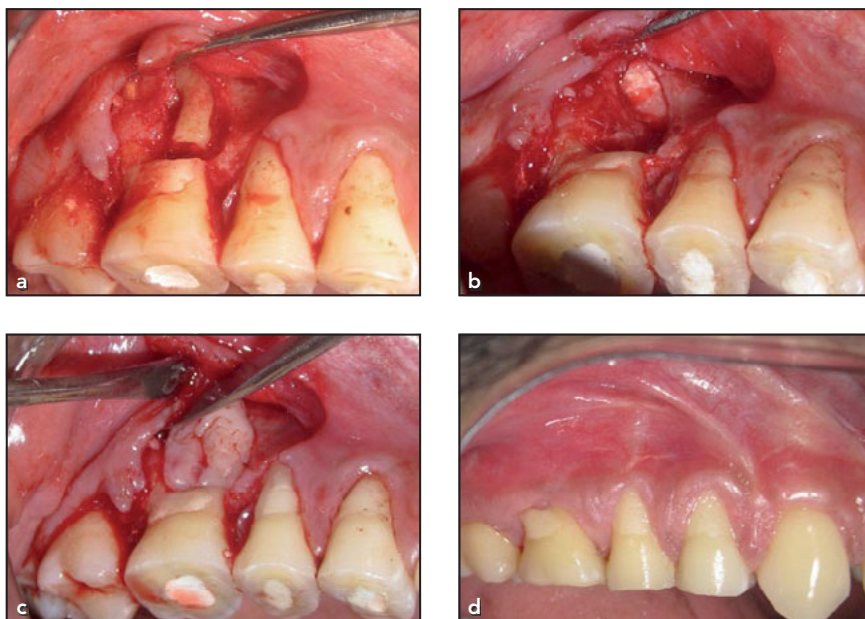


Fig 4 (a) Sectioning of the mesiobuccal root. (b) Collagen membrane used to plug the perforation into the maxillary sinus. (c) Socket of the extracted mesiobuccal root filled with a platelet-rich fibrin clot. (d) Healing at 3 months postoperative.

Discussion

PRF has an excellent track record as a biomaterial that encourages healing. Numerous applications of PRF have been described, ranging from implant-site grafting to wound healing.⁹ Factors leading to the popularity of this grafting material are the relative ease of obtaining it and the absence of risks, such as rejection or allergy.

The decision to use PRF as the sole grafting material in the present case series was made because these lesions indicated sites of chronic infection. Introduction of alloplastic materials, allografts, or xenografts at these sites may have introduced an added risk of infection.⁷ PRF, being an autologous fibrin scaffold, does not carry this risk. Additionally, there is evidence to show that such large intrabony defects undergo

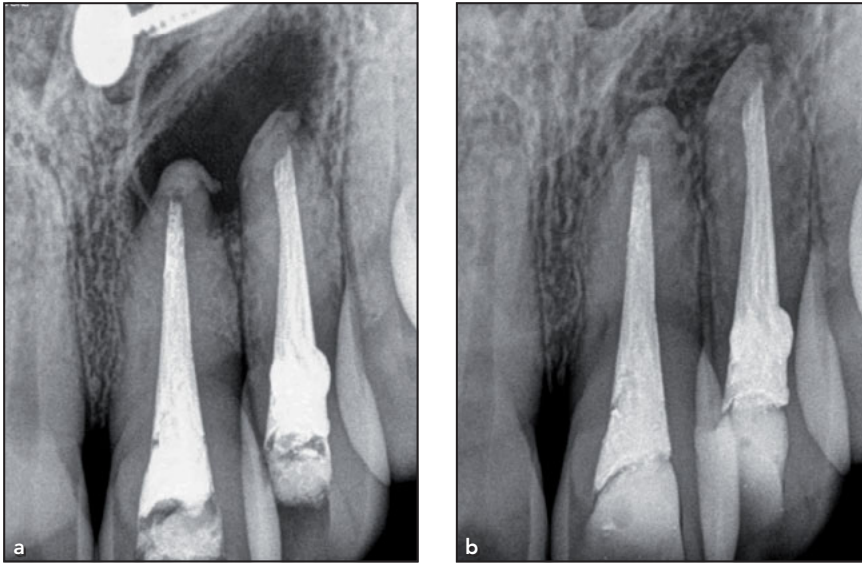


Fig 5 (a) Preoperative radiograph showing the periapical bone defect. (b) 1-year recall radiograph showing bone fill in the periapical bone defect.

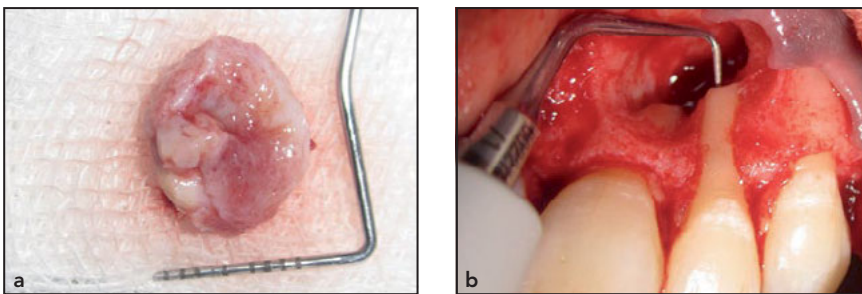


Fig 6 (a) Intact cyst after enucleation. (b) Retrograde cavity preparation using an ultrasonic tip. (c) Cyst cavity filled with a platelet-rich fibrin clot. (d) Collagen membrane used to cover the entire bone defect.

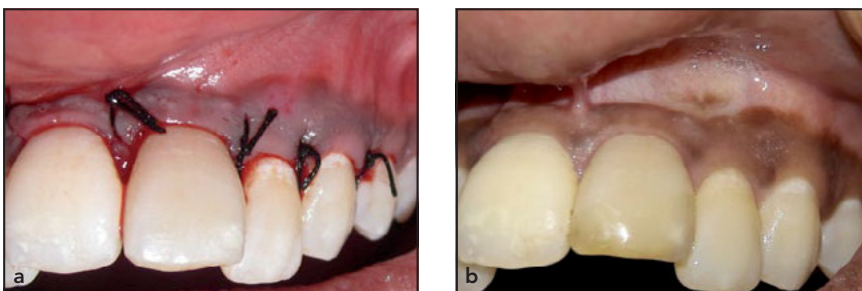
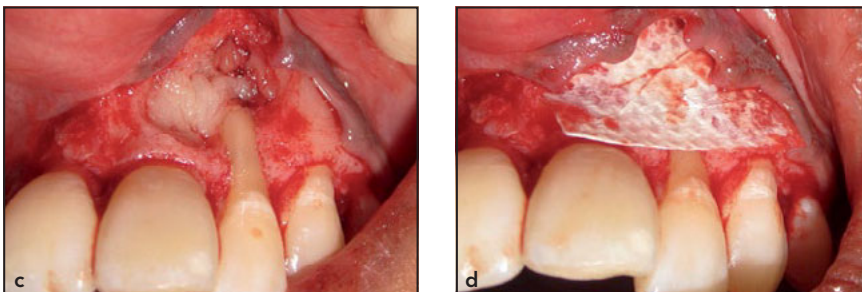


Fig 7 (a) Wound closure obtained using braided silk sutures. (b) Soft tissue healing at the 1-year recall visit.

spontaneous healing without the need for a graft.^{2,3} Keeping this evidence in mind, PRF was used to expedite this process of spontaneous healing.

The PRF clot used in the present case series was prepared according to Choukroun's original protocol—whole blood was withdrawn and immediately centrifuged at 3,000 rpm for 10 minutes without an anti-coagulant.⁸ Many variants of platelet concentrates have now come into use. These include pure platelet-rich plasma (P-PRP) and leukocyte- and platelet-rich fibrin (L-PRF), among others.¹⁰ The efficacy of all these materials and their superiority to conventional graft materials still remains to be proven.⁹ The relative lack of mechanical strength and fast rate of absorption are factors that limit the therapeutic usage of PRF to applications in early wound healing and clot stabilization. The present case series aimed to highlight the fact that PRF is a good material to support and encourage healing of wounds that may also heal without an additional graft. PRF may help the natural healing process by providing a stable fibrin scaffold for initial clot stabilization and growth factors.⁸ Efficacy of PRF in soft tissue wound healing and reduction of postoperative pain has been documented.¹¹ In a wound, the initial inflammatory process strives to replace the red blood cell clot with a fibrin scaffold. The use of PRF may help to hasten this process by providing a ready-made fibrin meshwork for the ingrowth of granulation

tissue and thereby reduce the associated inflammatory response. Due to this, the use of PRF may also contribute towards reduced patient morbidity in terms of pain and post-operative edema.

Conclusions

In the three cases presented, excellent bone fill was observed in the periapical defects grafted solely with PRF. Well-designed randomized controlled trials are needed to accumulate high-quality evidence for the use of PRF in various clinical scenarios.

Acknowledgments

The authors would like to acknowledge the support of the Departments of Periodontics and Operative Dentistry at Manipal College of Dental Sciences, Manipal. The authors declare no conflicts of interest.

References

1. Ramachandran Nair PN. Non-microbial etiology: Periapical cysts sustain post-treatment apical periodontitis. *Endod Topics* 2003;6:96–113.
2. Maalouf EM, Gutmann JL. Biological perspectives on the non-surgical endodontic management of periradicular pathosis. *Int Endod J* 1994;27:154–162.
3. Çalışkan MK. Prognosis of large cyst-like periapical lesions following nonsurgical root canal treatment: A clinical review. *Int Endod J* 2004;37:408–416.
4. Katsamakias S, Slot DE, Van der Sluis LW, Van der Weijden F. Histological responses of the periodontium to MTA: A systematic review. *J Clin Periodontol* 2013;40:334–344.
5. Santos Soares SM, Brito-Júnior M, de Souza FK, et al. Management of cyst-like periapical lesions by orthograde decompression and long-term calcium hydroxide/chlorhexidine intracanal dressing: A case series. *J Endod* 2016;42:1135–1141.
6. Lin L, Chen MY, Ricucci D, Rosenberg PA. Guided tissue regeneration in periapical surgery. *J Endod* 2010;36:618–625.
7. Li J, Wang HL. Common implant-related advanced bone grafting complications: Classification, etiology, and management. *Implant Dent* 2008;17:389–401.
8. Dohan DM, Choukroun J, Diss A, et al. Platelet-rich fibrin (PRF): A second-generation platelet concentrate. Part I: Technological concepts and evolution. *Oral Surg Oral Med Oral Pathol Oral Radiol Endod* 2006;101:e37–e44.
9. Miron RJ, Zucchelli G, Pikos MA, et al. Use of platelet-rich fibrin in regenerative dentistry: A systematic review. *Clin Oral Investig* 2017;21:1913–1927.
10. Dohan Ehrenfest DM, Rasmusson L, Albrektsson T. Classification of platelet concentrates: From pure platelet-rich plasma (P-PRP) to leukocyte- and platelet-rich fibrin (L-PRF). *Trends Biotechnol* 2009;27:158–167.
11. Kulkarni MR, Thomas BS, Varghese JM, Bhat GS. Platelet-rich fibrin as an adjunct to palatal wound healing after harvesting a free gingival graft: A case series. *J Indian Soc Periodontol* 2014;18:399–402.